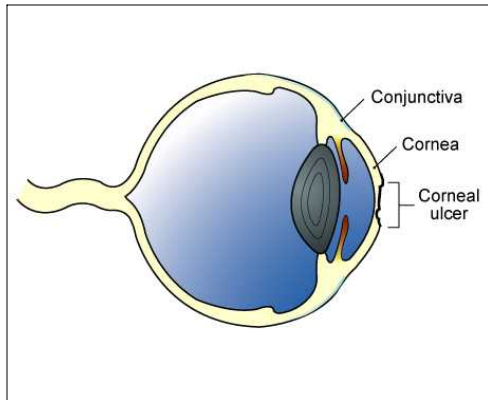


CORNEAL ULCERS

The cornea is the clear, shiny membrane that makes up the surface of the eyeball. It is much like a clear window. To understand a corneal ulcer, you must first understand how the cornea is constructed.



The cornea is comprised of three layers. The most superficial or outermost layer is the *epithelium*. This layer is comprised of many, very thin layers of cells, similar to an onion's skin. Below the epithelium is the *stroma* and the deepest layer is *Descemet's membrane*. Because all of these layers are clear, it is not possible to see them without special stains and a microscope.

Erosion through a few layers of the epithelium is called a *corneal erosion* or *corneal abrasion*. A *corneal ulcer* is an erosion through the entire epithelium and down into the stroma. If the erosion goes through the epithelium and stroma to the level of Descemet's membrane, a *descemetocoele* exists. If Descemet's membrane ruptures, the liquid inside the eyeball leaks out and the eye collapses.

What causes corneal ulcers?

There are several causes for corneal ulcers in cats. The most common is trauma. An ulcer may result from blunt trauma, such as a cat rubbing its eye on a carpet, or due to a laceration, such as a cat-claw scratch. The second most common cause is chemical burn of the cornea. This may happen when irritating shampoo or dip gets in the eye.

Less common causes of corneal ulcers include bacterial infections, viral infections, and other diseases. These may originate in the eye or develop secondary to disease elsewhere in the body.

What are the clinical signs of corneal ulcers?

A corneal ulcer is very painful. In response to pain, most cats rub the affected eye with a paw or on the carpet or furniture. To protect the eye, they keep the lids tightly closed. Occasionally, there will be a discharge that collects in the corner of the eye or runs down the face.

How is a corneal ulcer diagnosed?

Superficial corneal abrasions are usually not visible without the aid of special equipment and stains. Corneal ulcers are most often highlighted and seen with the use of fluorescein stain. A drop of this orange-colored stain is placed on the cornea. The dye will adhere to an area of ulceration and is easily visualized, sometimes requiring the use of a special black light called a Wood's light. This is the most basic test performed and may be the only test needed if the ulcer is acute and very superficial. If the ulcerated area is chronic or very deep, samples are taken for culture and cell study prior to applying the stain or any other medication.

How is a corneal ulcer treated?

The form of treatment used depends on whether there is a corneal abrasion, corneal ulcer, or descemetocoele present.

Corneal abrasions generally heal within three to five days. Medication is used to prevent bacterial infections (antibiotic ophthalmic drops or ointment) and to relieve pain (atropine ophthalmic drops or ointment). Antibiotic drops are only effective for a few minutes so they must be applied frequently; ointments last a bit longer but still require application every few hours. It is suggested that an antibiotic preparation be instilled in the eye four to six times per day. On the other hand, the effects of atropine last many hours so this drug is only used once or twice daily.

If a corneal ulcer or descemetocoele is present, measures must be taken to protect the eye and to promote healing. Since cats do not wear eye patches well, surgical techniques are often used to close the eyelids and cover the ulcer or descemetocoele. These measures protect the eye for several days and then are reversed so the cat can use the eye again.

Ulcers that do not heal well often have a buildup of dead cells at the ulcer edge. These dead cells prevent normal cells from the corneal surface from sliding over the ulcer edge and filling in the defect. If this appears to be part of the healing problem, the dead cells are removed from the edges of the ulcer before the eyelids are surgically closed. In some cases, removing the dead cells may be all that is needed to start the healing process, so surgical closing of the eyelids may not be necessary. The most common surgical technique to promote healing in this situation is a *corneal debridement* followed by a *grid keratectomy*.

Is there a difference between a corneal ulcer and a corneal abrasion?

It is easy to confuse an ulcer and an abrasion on the first examination. There is a judgment call involved in differentiating the two. After two to three days of treatment, your cat should be reexamined to be sure that healing is progressing properly. If that does not happen, a decision may be made to perform surgery.

Do any of the medications have side-effects?

A cat will rarely be allergic to an antibiotic that is instilled in the eye. If your cat seems to be in more pain after the medication is used, discontinue it and contact your veterinarian.

A cat with a corneal ulcer has quite a bit of pain in the eye, so it keeps it tightly shut. Atropine is used to relieve that pain. However, atropine also dilates the pupil widely. This means that the cat is very sensitive to light in that eye. Because of the light sensitivity, the eye will be held closed in bright light.



Atropine's effects may last for several days after the drug is discontinued. Do not be alarmed if the pupil stays dilated for several days. Should you accidentally get atropine in your eye, the same prolonged pupillary dilation will occur.

Atropine has a very objectionable taste. If it gets in the cat's mouth, drooling will occur. This is not a drug reaction but a reaction to the terrible taste. It will subside in a few minutes. However, once this happens, the cat may be more difficult to medicate because it may anticipate the same thing happening again.

What can I use to control the pain?

A topical anesthetic is often used to numb the cornea so diagnostic tests may be performed. However, these drugs are toxic to the corneal epithelium and prevent proper healing. They are safe for one time use, but they should not be used as part of the treatment.

How do I know when the treatment is completed?

The best way to tell that the cornea has healed is to repeat the fluorescein stain test. This should be done after approximately five to seven days of treatment.

What does it mean if there are red streaks near the ulcer?

The normal cornea has no blood vessels going through it. However, when a corneal ulcer or descemetocoele occurs, the body senses a need to increase its healing capabilities. New blood vessels are created by a process called *neovascularization*. The new vessels begin at the sclera or the white part of the eye and grow toward the ulcer.

Neovascularization is a positive response because it indicates healing and hastens recovery. However, after the ulcer is healed, these vessels may remain in the cornea. They are not painful, but they can obstruct vision. Therefore, it is desirable to attempt to remove them. This is done with steroid ophthalmic drops or ointment. Corticosteroids are used for a few days to several weeks, depending on how many blood vessels exist.

It is important that steroids are not used in the eye too soon because they will stop healing of a corneal ulcer and may worsen it. Therefore, the fluorescein dye test should be performed before beginning this type of medication. If steroids are used and pain occurs in the eye again, discontinue the steroids and have the eye rechecked.

*This client information sheet is based on material written by Ernest Ward, DVM
© Copyright 2005 Lifelearn Inc. Used with permission under license. February 10, 2008*